

Change in Thrombus Length on Venous Ultrasound and Recurrent Deep Vein Thrombosis

Lori-Ann Linkins, MD; Patricia Pasquale, RDMS; Sharon Paterson, RDMS; Clive Kearon, MB, PhD

Background: Despite successful treatment, deep vein thrombosis may not fully resolve in some patients. Consequently, in patients with new symptoms in a previously affected leg, noncompressibility on ultrasound cannot be assumed to be due to recurrent thrombosis; therefore, we sought to determine interobserver agreement on ultrasound measurements of thrombus length and identify the change in length that is likely to indicate thrombus extension.

Methods: Cross-sectional study of patients with previous proximal deep vein thrombosis and residual ultrasound abnormalities, but without symptoms suggestive of recurrence. The patients had a standardized series of measurements of thrombus length independently performed by 2 ultrasonographers. The outcome measure was the agreement between the ultrasonographers on the distance of thrombus margins from 4 anatomical landmarks.

Results: There was good interobserver agreement on thrombus length when measured from the saphenofemoral junction, mid-popliteal fossa, and mid-patella (93% or more of the variance was accounted for by the paired measurements). Using these landmarks, the 95th percentile for the absolute difference between paired measurements was 8.9 cm for the saphenofemoral junction, 8.5 cm for the mid-popliteal fossa, and 8.4 cm for the mid-patella.

Conclusions: When 2 ultrasound examinations are compared, an apparent increase in thrombus length of 9 cm or greater is likely to be supportive of a diagnosis of recurrent deep vein thrombosis. Increases in thrombus length of less than 9 cm appear to be within the bounds of measurement error.

Arch Intern Med. 2004;164:1793-1796

ULTRASOUND IMAGING IS AN accurate diagnostic test for a first episode of proximal deep vein thrombosis. A lack of full compressibility of the vein lumen when pressure is applied with an ultrasound probe indicates that thrombus is present, whereas full compressibility excludes thrombosis.^{1,2} Despite successful treatment, many deep vein thrombi do not fully resolve and leave abnormal ultrasound findings, including persistent noncompressibility.^{3,4} Consequently, in patients with new symptoms in a leg with previous venous thrombosis, noncompressibility on ultrasound cannot be assumed to be due to recurrent thrombosis.

To diagnose recurrent deep vein thrombosis with ultrasound, it is necessary to establish that new (ie, acute) thrombosis has occurred. Noncompressibility of a common femoral or popliteal vein that was previously compressible is universally accepted as diagnostic of recurrent

deep vein thrombosis.^{1,3,4} However, as postresolution ultrasounds are seldom available for comparison, and as thrombus may recur in the same venous segment, this finding is uncommon.^{3,4} An additional criterion for the ultrasound diagnosis of recurrence in patients with a previous ultrasound evaluation would be a convincing increase in the length of the thrombus when the evaluation is repeated. Unfortunately, unlike contrast venography, ultrasound imaging does not clearly show other structures in the leg (eg, bones) that can serve as reference points to determine if thrombus margins have changed position between examinations. Consequently, there are no validated criteria to identify extension of thrombus length on ultrasound evaluation.

To determine the accuracy of ultrasound measurements of thrombus length, and to identify differences in measurements of length that would support a diagnosis of recurrent thrombosis, we performed ultrasound examinations of the

From the Department of Medicine, McMaster University (Drs Linkins and Kearon), and the Department of Radiology, Hamilton Health Sciences Corporation, Henderson Site (Mss Pasquale and Paterson), Hamilton, Ontario. The authors have no relevant financial interest in this article.

proximal deep veins on 2 occasions in patients with previous deep vein thrombosis and residual ultrasound abnormalities.

METHODS

PATIENT POPULATION

Patients who were likely to have residual ultrasound abnormalities were identified from thrombosis clinic records. These were either patients who had proximal deep vein thrombosis diagnosed in the past 3 months or patients who had incomplete compressibility of the proximal veins on an ultrasound examination performed 3 or more months after diagnosis. They were invited to take part in a study evaluating the reproducibility of venous ultrasound measurements. The study was approved by the Hamilton Health Sciences Research Ethics Board and patients provided written informed consent.

Of the 60 patients who were evaluated, 30 (50%) were women and 2 had a history of bilateral deep vein thrombosis. The mean patient age was 61 years (range, 28-89 years) and the mean time since the last episode of symptomatic deep vein thrombosis was 7 months (range, 0.4-49 months).

ULTRASOUND EXAMINATIONS

On the same day and in random order, 2 experienced examiners (P.P. and S.P.) performed a standardized series of ultrasound measurements for each patient using an Elegra scanner with a 7.5-MHz linear-array transducer (Siemens, Issaquah, Wash). Each examiner used the same scanner throughout the study. Both were blinded to the original clot location, and they independently recorded their findings on standardized forms. Patients were asked not to comment on the findings of the first examination when undergoing the second examination. Ultrasound examination was confined to the proximal deep veins of both legs (ie, from the common femoral vein to the calf trifurcation); the iliac and calf veins were not examined. The only criterion used to identify residual deep vein thrombosis and to document thrombus extent was the inability to fully compress the vein lumen.

When a thrombus was seen, thrombus length was measured as follows: upper and/or lower thrombus margins, defined as the point of transition from full compressibility to incomplete compressibility, were identified using compression ultrasound in the transverse plane and marked on the skin using removable adhesive tape; then, distance from the thrombus margins to each of 4 landmarks—inguinal ligament, saphenofemoral junction, mid-popliteal fossa, and mid-patella—was measured with a tape measure. The inguinal ligament was identified as the midpoint of a line between the symphysis pubis and the anterior superior iliac spine. The saphenofemoral junction was identified by ultrasound imaging, the mid-popliteal fossa was identified as the most prominent crease in the popliteal fossa, and the mid-patella was identified as the midpoint of an imaginary line drawn between the cranial and caudal poles of the patella.

STATISTICAL ANALYSIS

It was estimated that 50 patients with residual proximal deep vein thrombosis would need to be examined to obtain a reliable estimate of interobserver variability of the measurement of thrombus length. Least-squares regression analysis was used to assess agreement between observers; the r^2 value corresponds to the proportion of variance accounted for by the paired

measurements. Interobserver differences for paired measurements were expressed as absolute values and plotted as histograms, and the 95th percentile was identified using linear interpolation. Statistical analyses were performed using Minitab 13 software (version 13; Minitab Inc, State College, Pa).

RESULTS

The examiners agreed that there was no residual thrombus in 10 legs and that thrombus was present in 42 of the 62 legs with previously documented proximal deep vein thrombosis. They disagreed on the presence or absence of thrombus in 10 legs. They agreed that, of 84 potential thrombus margins (proximal and distal margins for the 42 thrombi), the proximal margin of 1 thrombus and the distal margin of 22 thrombi could not be located because the thrombus extended beyond the field of examination (ie, into the pelvis and calf, respectively), and they agreed that 49 margins were present. They disagreed on the presence or absence of 12 thrombus margins.

When both examiners located the same thrombus margin, there was good interobserver agreement on the distance of the thrombus margin from each of the 4 anatomical landmarks. The variance accounted for by paired measurements, ie, r^2 , was 89% for the inguinal ligament, 93% for the saphenofemoral junction, 95% for the mid-popliteal fossa, and 93% for the mid-patella (**Figure 1**). The 95th percentile for the absolute difference in thrombus length between examiners was 10.9 cm for the inguinal ligament, 8.9 cm for the saphenofemoral junction, 8.5 cm for the mid-popliteal fossa, and 8.4 cm for the mid-patella (**Figure 2**).

COMMENT

This study suggests that a change in thrombus length, when measured in a standardized way, may indicate thrombus extension and support a diagnosis of recurrent deep vein thrombosis. The 4 landmarks we used as reference points (3 on the body surface and 1 located on ultrasound examination) are easily identified in most patients. Interobserver agreement was similar when using the saphenofemoral junction, the mid-popliteal fossa, and the mid-patella as reference landmarks. Measurements appeared to be less precise when the inguinal ligament was used. With the use of any of the 3 best landmarks, it appears that an increase in thrombus length of 9 cm or greater between 2 ultrasound examinations is likely due to true thrombus extension; smaller differences could occur through measurement error.

An increase of 5 cm in thrombus length on a second ascending contrast venography is generally accepted as evidence of extension.^{5,6} This criterion for extension is reasonable with venography because the position of the thrombus margin can be compared using adjacent bones as reference landmarks. We are not aware of previous studies that have evaluated the reproducibility of the measurement of thrombus length using ultrasound.

Although we chose to focus on thrombus length in this study, there are a number of other ultrasound measurements that have been used to diagnose recurrent deep vein thrombosis. Changes in thrombus diameter,

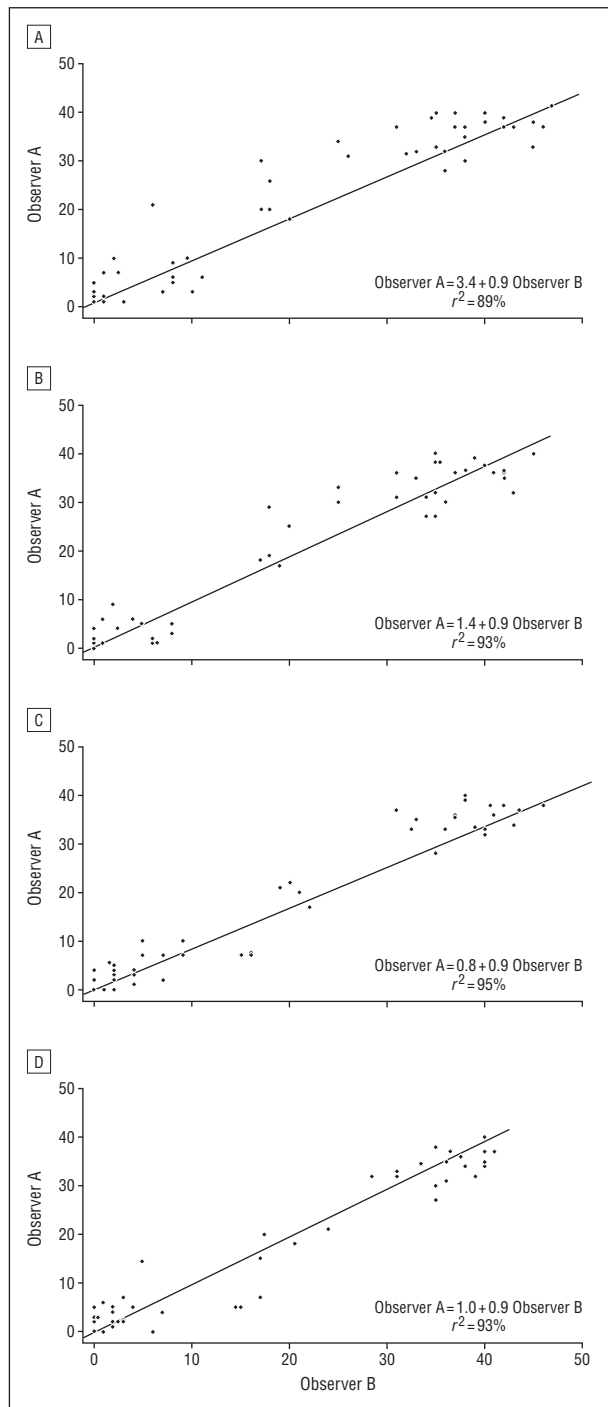


Figure 1. Interobserver agreement on measurement of distance of thrombus margins from 4 anatomical landmarks: A, inguinal ligament; B, saphenofemoral junction; C, mid-popliteal fossa; and D, mid-patella. The diagonal line corresponds to perfect agreement.

thrombus appearance, and Doppler assessment of venous flow have been suggested as criteria for differentiating acute thrombosis from chronic changes.^{1,4,7} With the exception of venous diameter,^{4,7} these criteria have not been systematically evaluated and there is currently no consensus on which ultrasound measurements are the most reliable for diagnosing recurrent deep vein thrombosis.

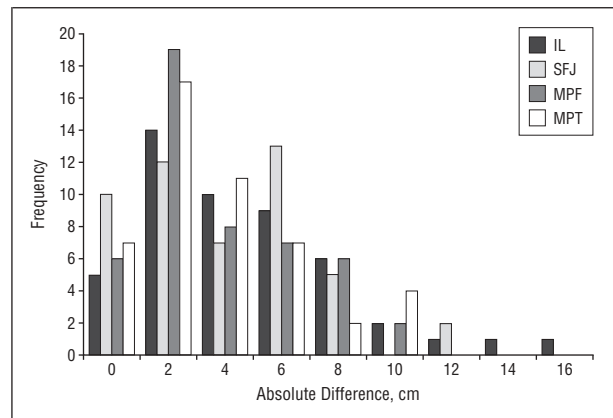


Figure 2. Absolute difference between observers in measurement of the distance between thrombus margins and 4 anatomical landmarks. IL indicates inguinal ligament; SFJ, saphenofemoral junction; MPF, mid-popliteal fossa; and MPT, mid-patella.

The findings of our study are likely to be valid because it was conducted prospectively by experienced ultrasonographers and according to a rigorous protocol. Biased assessment of agreement was avoided by ensuring that the ultrasonographers were blinded to both the original location of the patient's thrombus and the results of their colleague's examination.

A limitation of this study is the inability to differentiate between interobserver and intraobserver variability because each ultrasound examination was performed only once by each examiner. To evaluate intraobserver variability, patients would have had to return to our center, which unfortunately was not feasible. Consequently, we are unable to determine if the variability of the measurements would have been less if the 2 examinations had been performed by the same ultrasonographer. However, because patients who present with symptoms of recurrence often have their ultrasound repeated by a different examiner, the interobserver comparisons that were made reflect clinical practice.

We recognize that the ultrasound examinations for this study were performed by experienced, highly motivated ultrasonographers. Furthermore, agreement on thrombus length was only assessed for thrombus margins that both examiners were able to identify. Whether interobserver agreement on thrombus length would be as consistent in less experienced hands during routine clinical practice requires further evaluation.

In summary, when measured in a standardized way, an increase in thrombus length of 9 cm or greater between 2 ultrasound examinations is likely to represent thrombus extension and may support a diagnosis of recurrent proximal deep vein thrombosis. However, these findings are preliminary and this criterion for thrombus extension needs to be confirmed in a prospective clinical trial.

Accepted for publication December 15, 2003.

Dr Linkins's work was supported by a grant from the Hamilton Health Sciences Foundation, Hamilton, Ontario (an unrestricted research fellowship from the Thrombosis Interest Group of Canada in partnership with DuPont Canada, Mississauga, Ontario) and a fellowship from the

Heart & Stroke Scientific Research Corporation of Canada in partnership with AstraZeneca Inc, Mississauga.

Dr Kearon is a Scholar of the Heart & Stroke Foundation of Canada, Ottawa, Ontario.

We thank Karyn Lambert for her technical support and Jeff Weitz and Jeff Ginsberg for reviewing the manuscript.

Correspondence: Lori-Ann Linkins, MD, Henderson Research Centre, 711 Concession St, Hamilton, Ontario, Canada L8V 1C3 (llinkins@thrombosis.hhscr.org).

REFERENCES

1. Kearon C, Julian JA, Newman TE, et al. Noninvasive diagnosis of deep venous thrombosis. *Ann Intern Med.* 1998;128:663-677.
2. Lensing AWA, Prandoni P, Brandjes D, et al. Detection of deep-vein thrombosis by real-time B-mode ultrasonography. *N Engl J Med.* 1989;320:342-345.
3. Heijboer H, Jongbloets LMM, Buller HR, et al. Clinical utility of real-time compression ultrasonography for diagnostic management of patients with recurrent venous thrombosis. *Acta Radiol.* 1992;33:297-300.
4. Prandoni P, Cogo A, Bernardi E, et al. A simple ultrasound approach for detection of recurrent proximal-vein thrombosis. *Circulation.* 1993;88:1730-1735.
5. Schulman S, Rhedin AS, Lindmarker P, et al; Duration of Anticoagulation Trial Study Group. A comparison of six weeks with six months of oral anticoagulant therapy after a first episode of venous thromboembolism. *N Engl J Med.* 1995; 332:1661-1665.
6. Schulman S, Granqvist S, Holmstrom M, et al; Duration of Anticoagulation Trial Study Group. The duration of oral anticoagulant therapy after a second episode of venous thromboembolism. *N Engl J Med.* 1997;336:393-398.
7. Prandoni P, Lensing AWA, Bernardi E, et al. The diagnostic value of compression ultrasonography in patients with suspected recurrent deep vein thrombosis. *Thromb Haemost.* 2002;88:402-406.

Correction

Error in Address. In the article by Montanez et al titled "Prolonged QTc Interval and Risks of Total Cardiovascular Mortality and Sudden Death in the General Population: A Review and Qualitative Overview of the Prospective Cohort Studies" published in the May 10 issue of the ARCHIVES (2004;164:943-948), the location of the Agatston Research Institute and the address of the corresponding author were incorrectly given. The Agatston Research Institute location should have been given as Miami Beach, Fla, and the address for the corresponding author should have read Charles Hennekens, MD, 2800 S Ocean Blvd, PH-A, Boca Raton, FL 33432 (profchmd@prodigy.net).